

Flutter du toit en 8

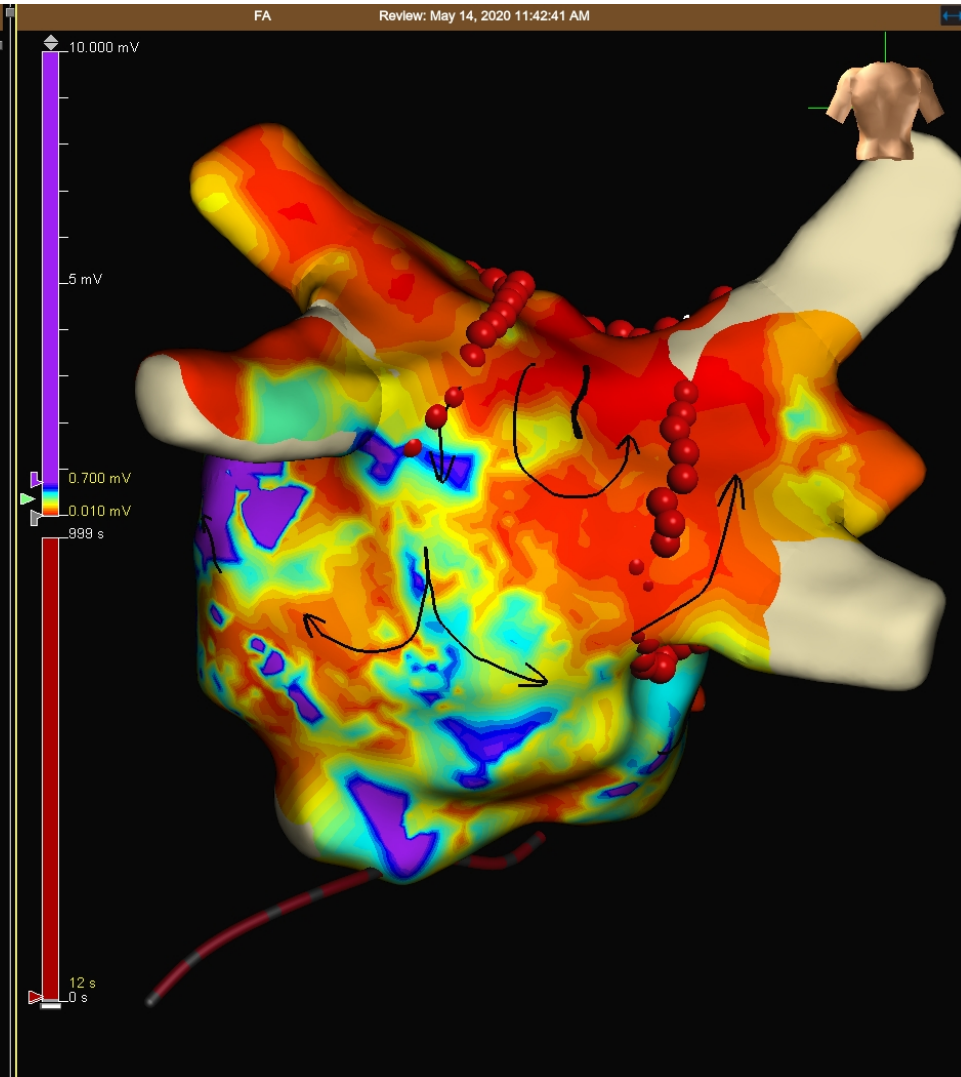
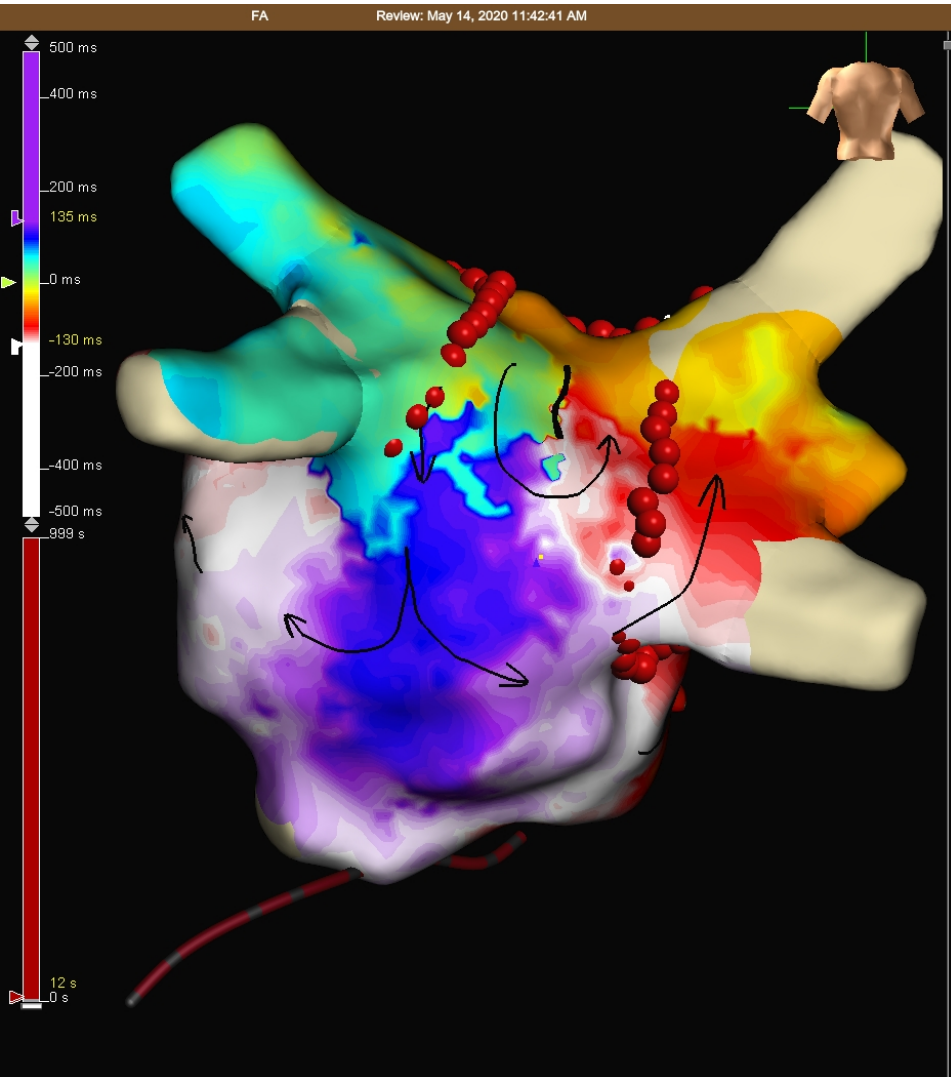
Dr Laurent Rosier & Dr Alexis Durand-Dubief.

Infirmierie Protestante - Mai 2020

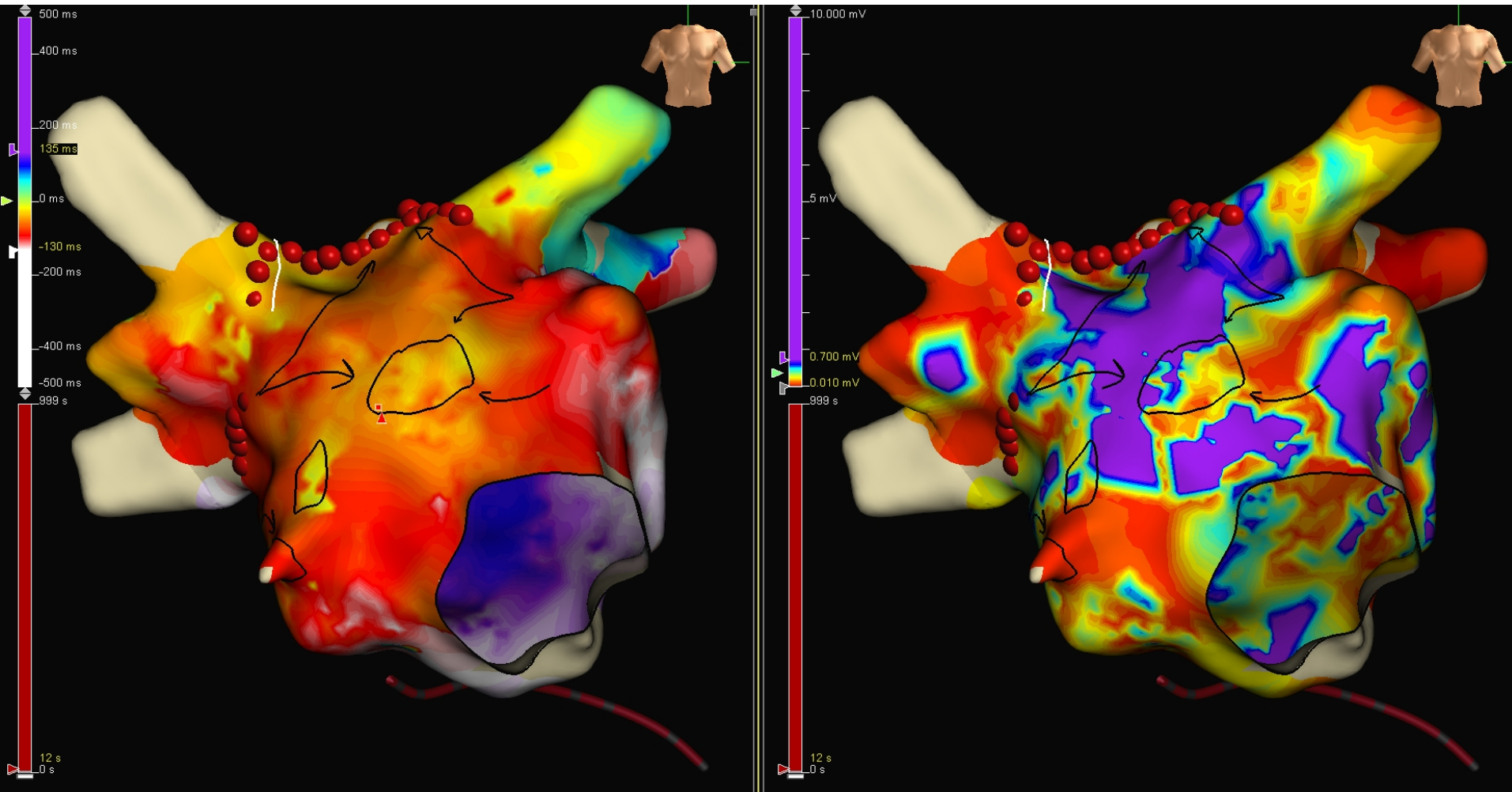
Historique patient

- Pas d'antécédent d'ablation.

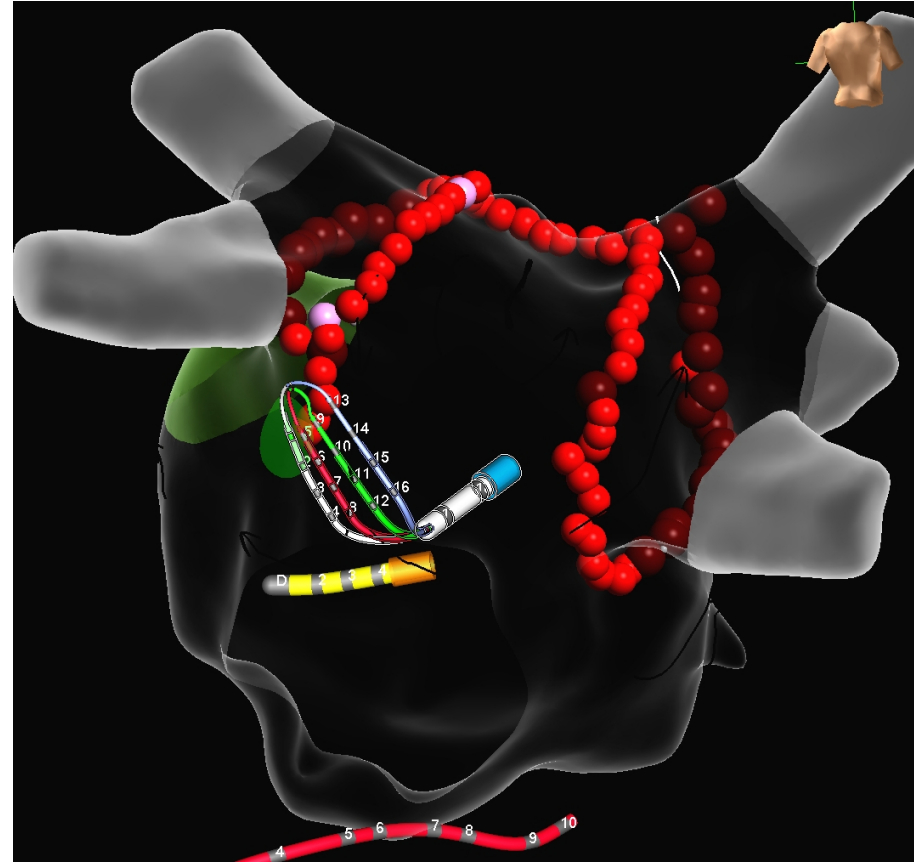
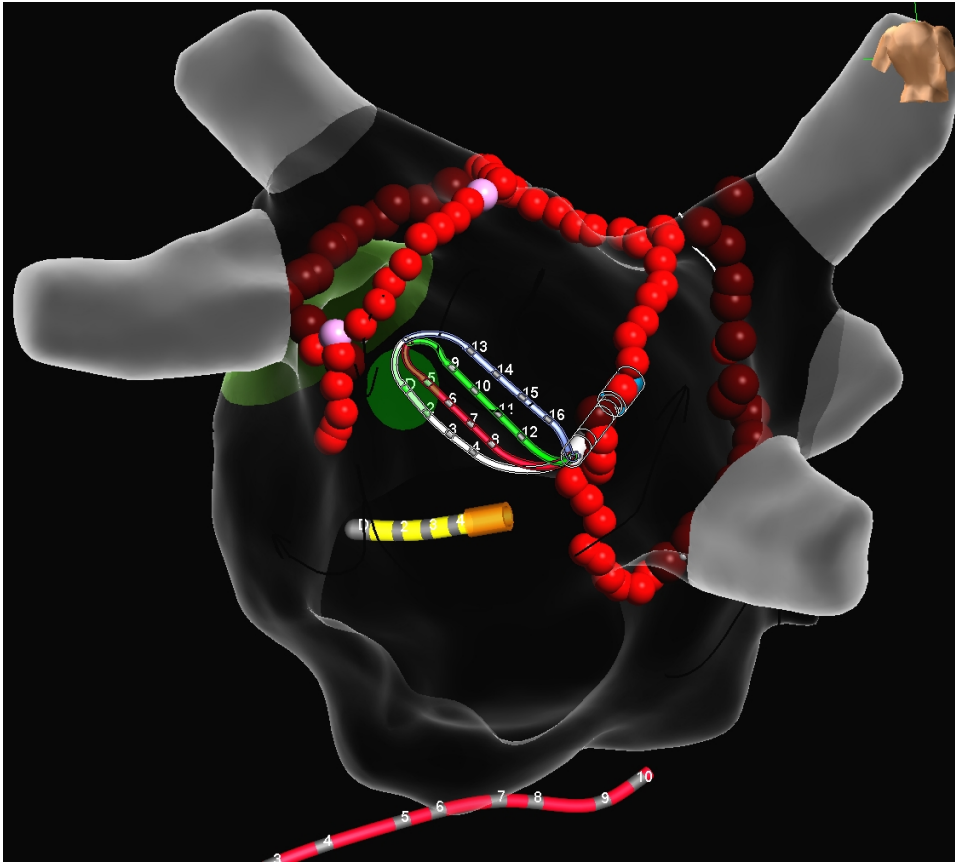
Cartographie : 290 ms / Voltage



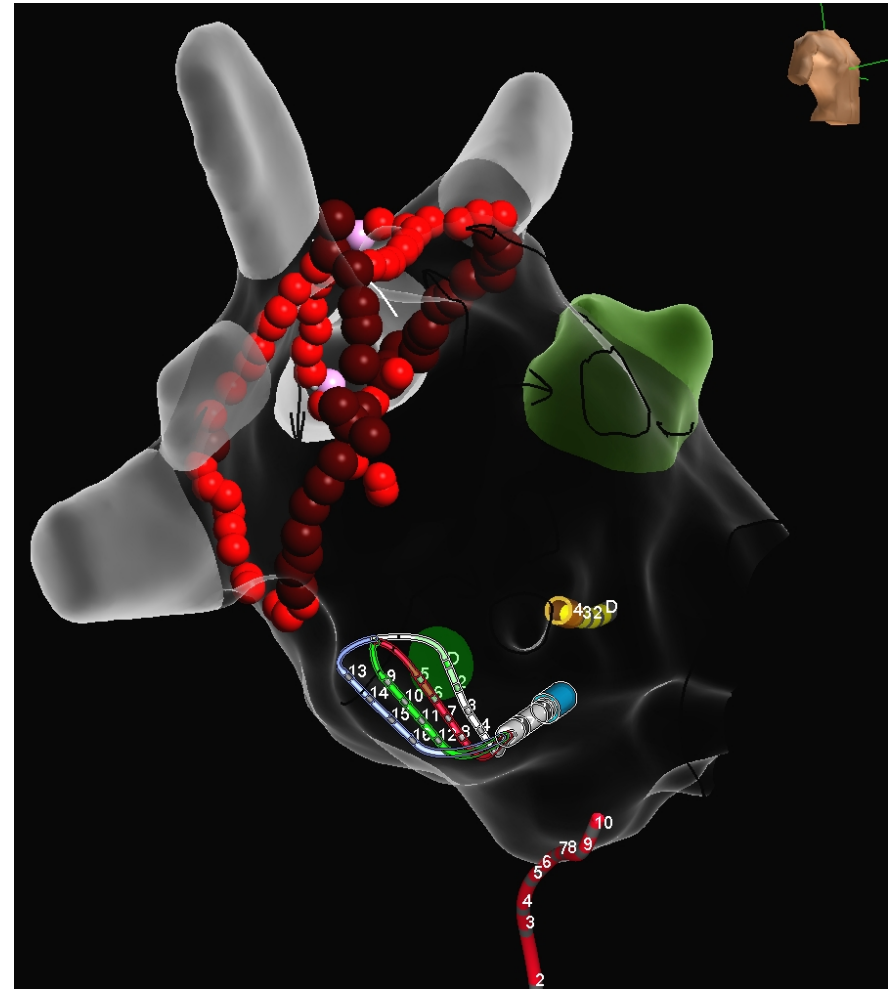
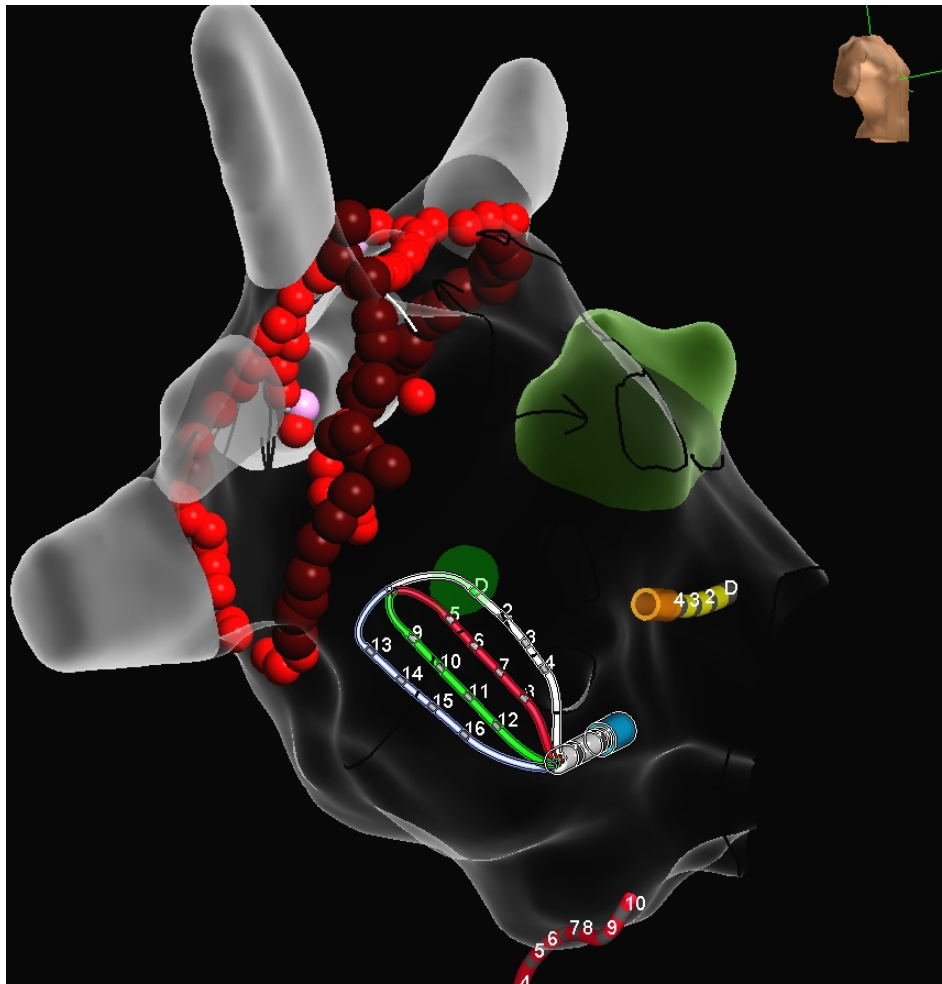
Cartographie : 290 ms / Voltage



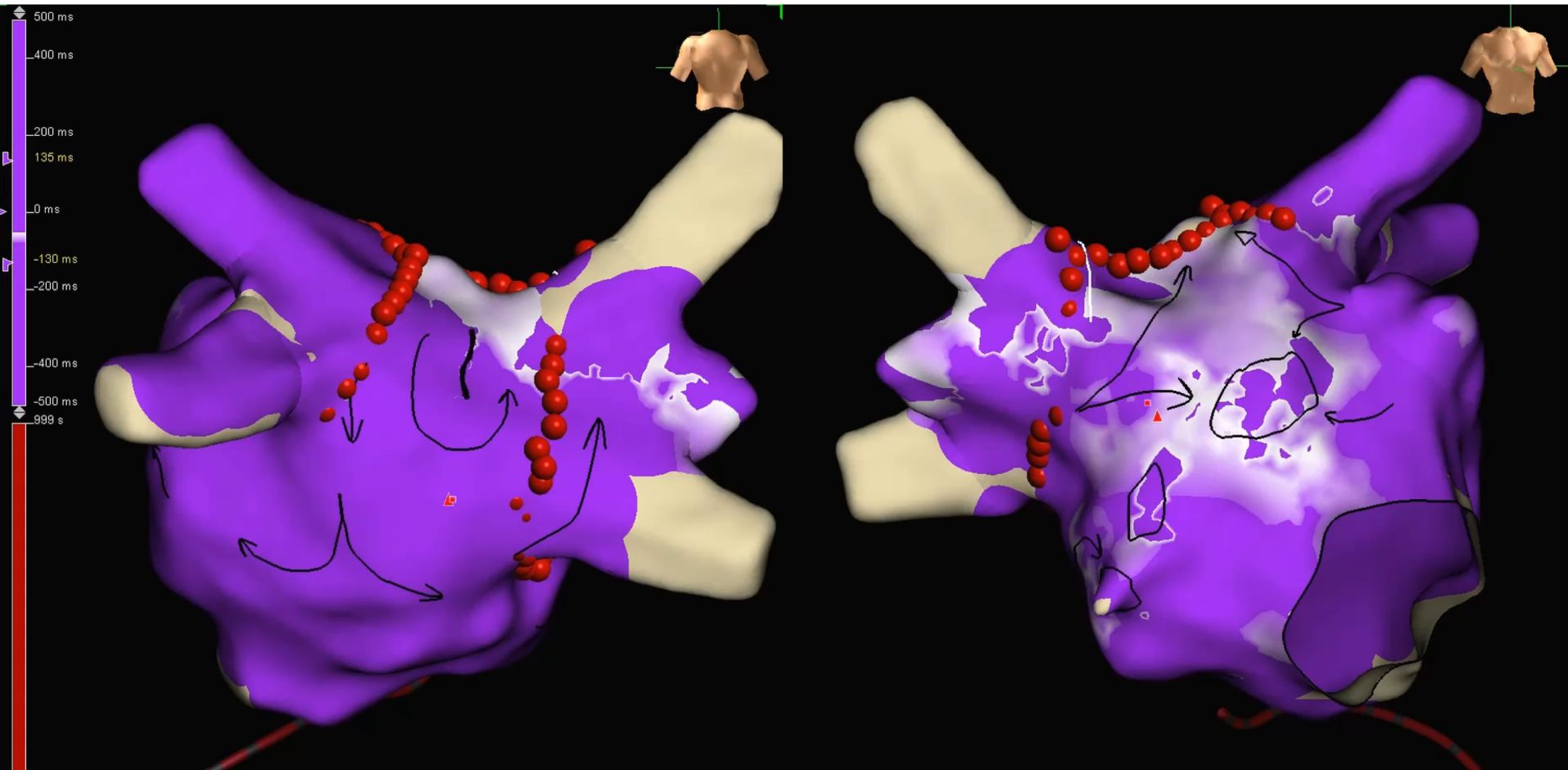
HD Grid postérieur



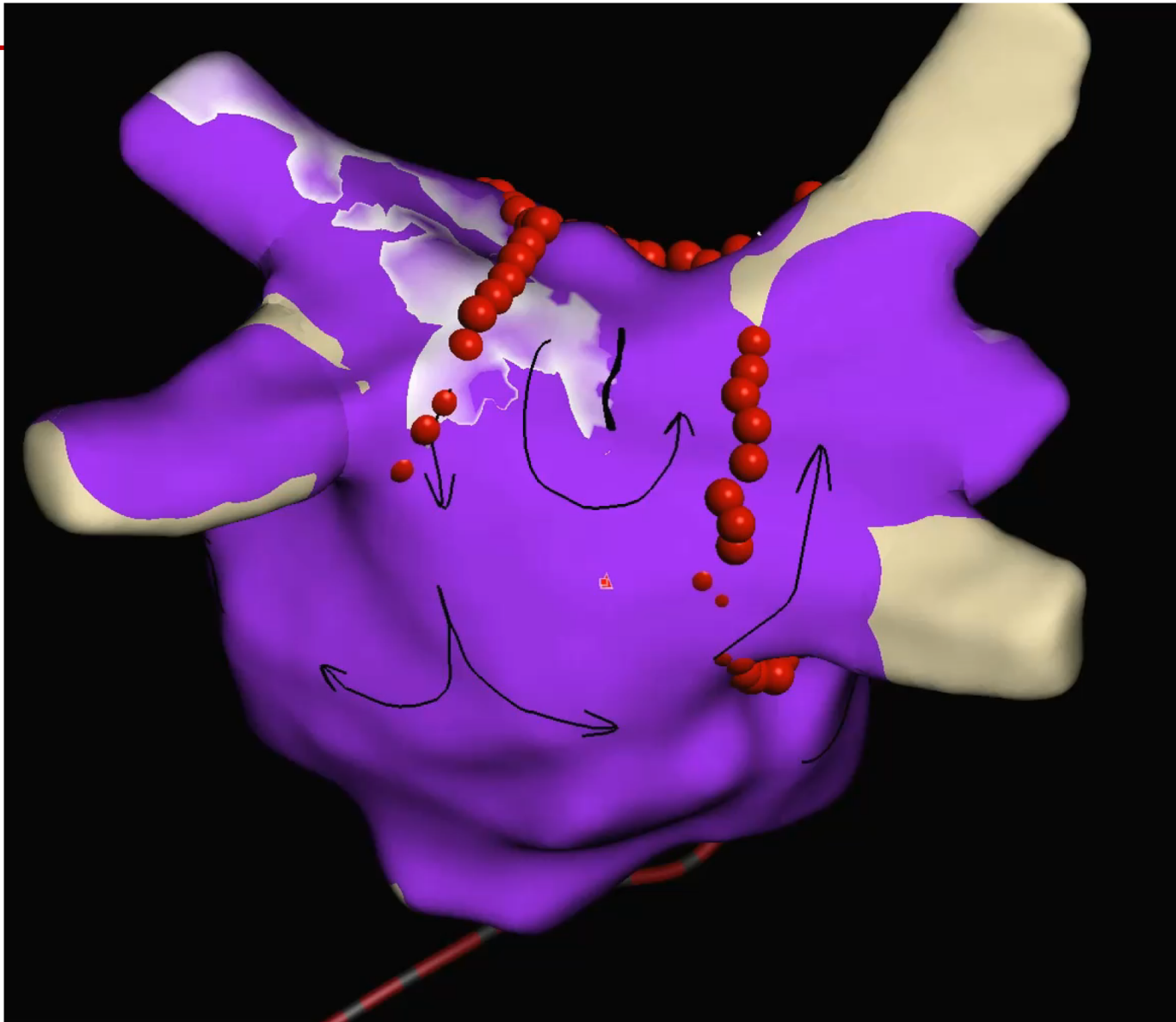
HD Grid septum



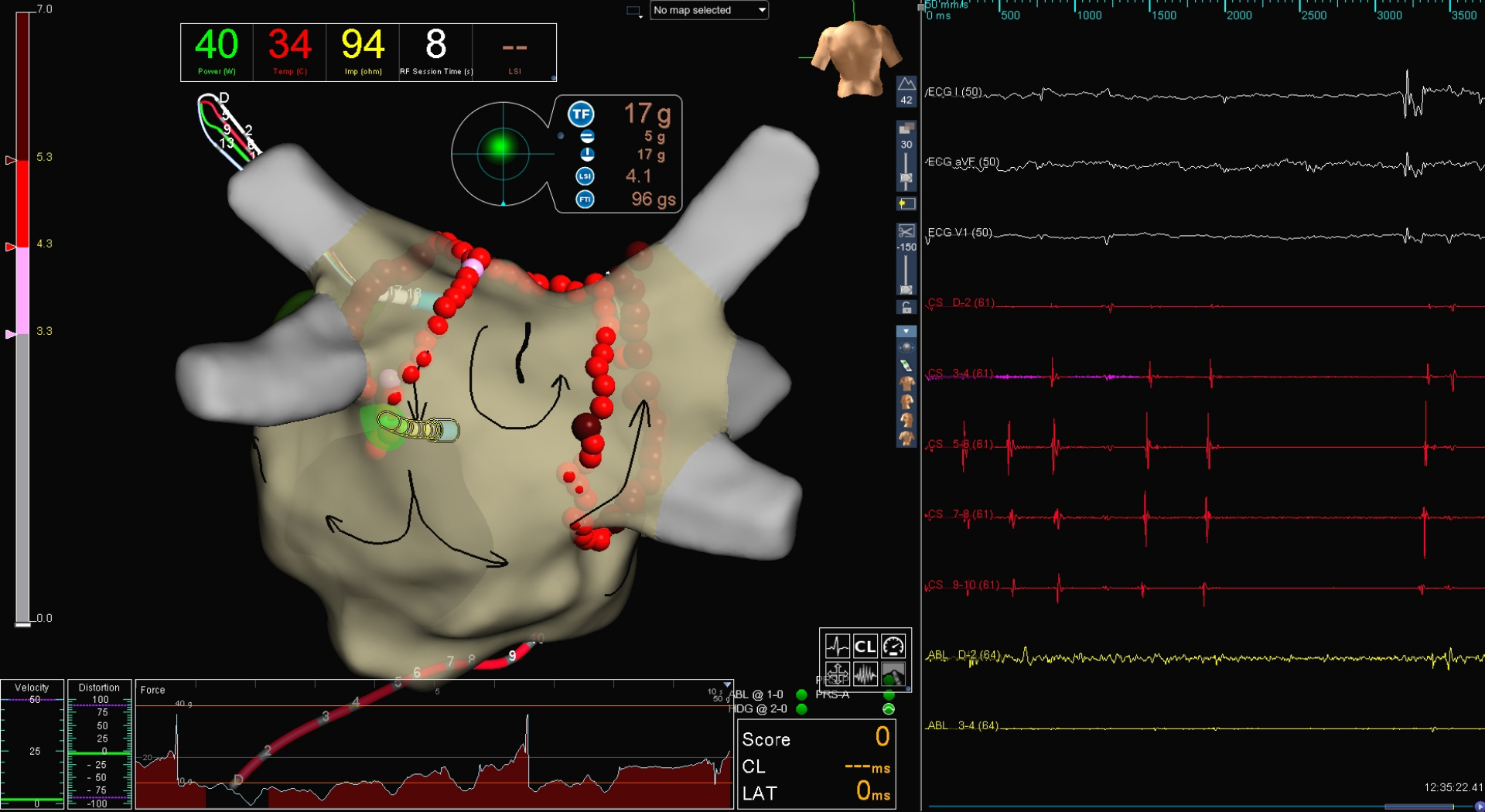
Activation du circuit 290 ms



Activation du circuit 290 ms



Retour sinusal



Contrôle bloc du toit

